

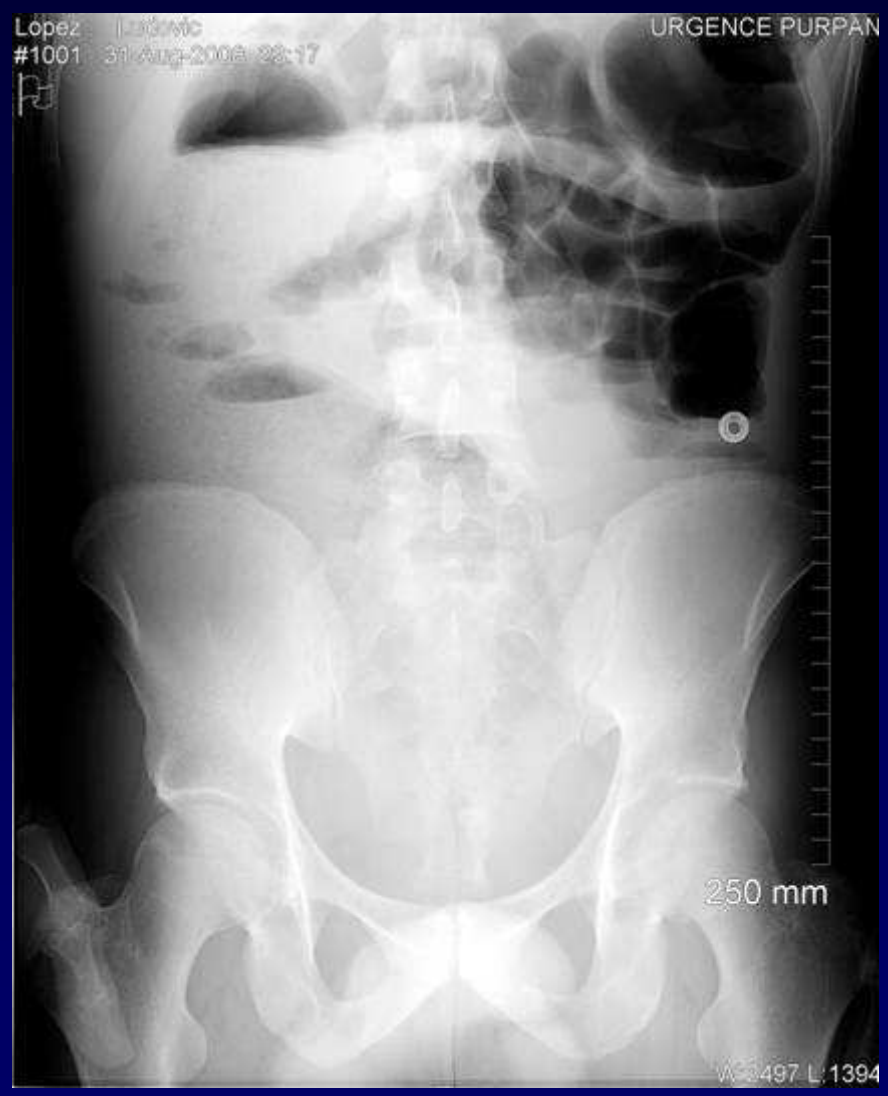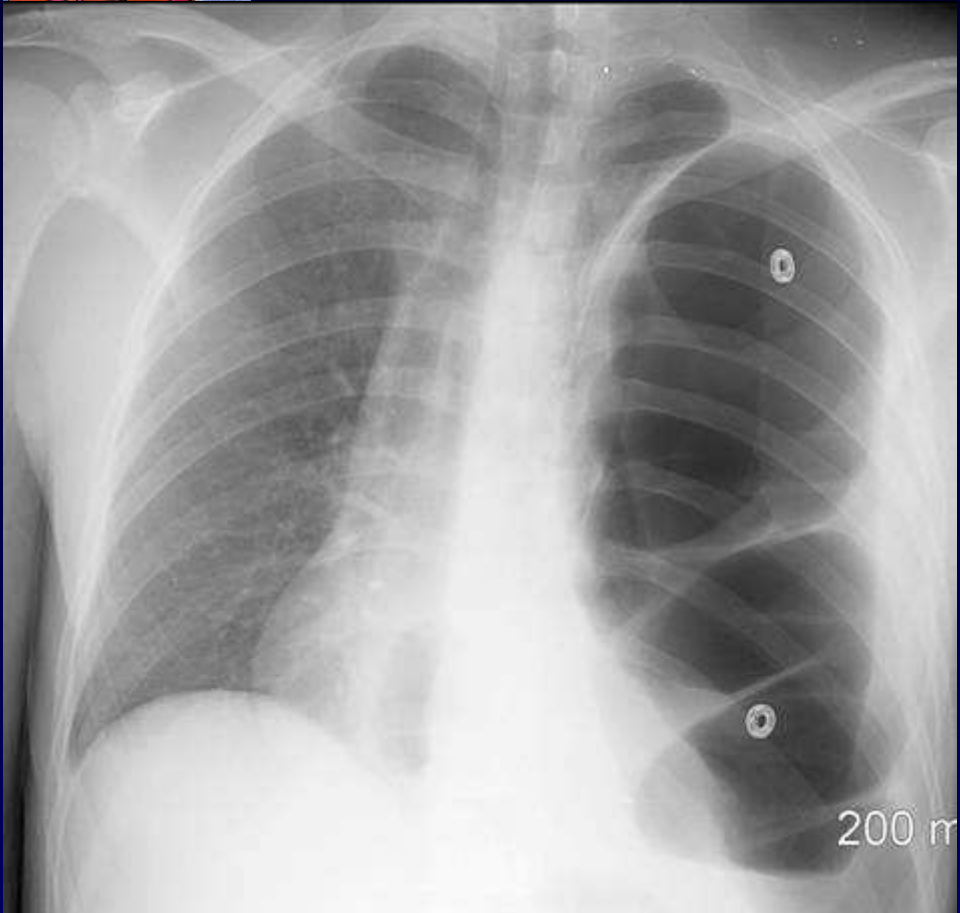

Dossier 4

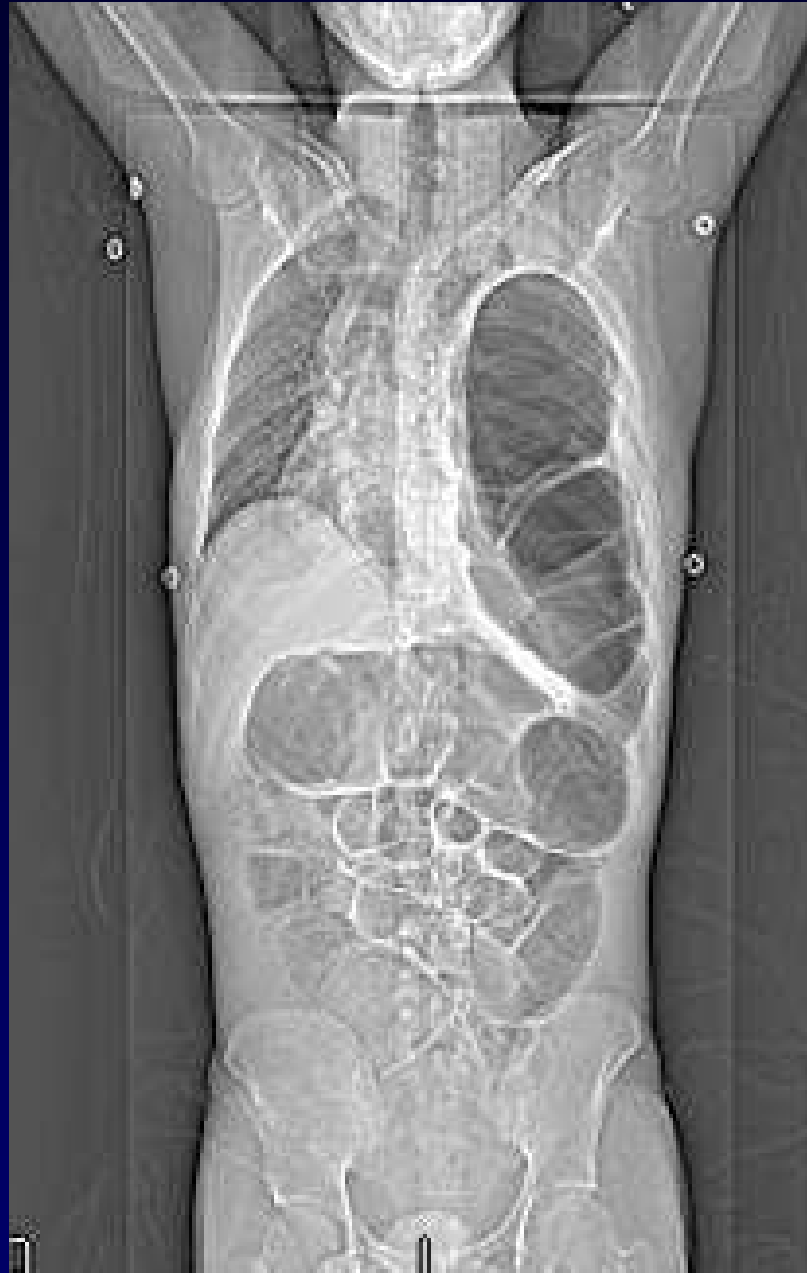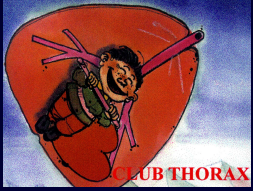
J. GIRON

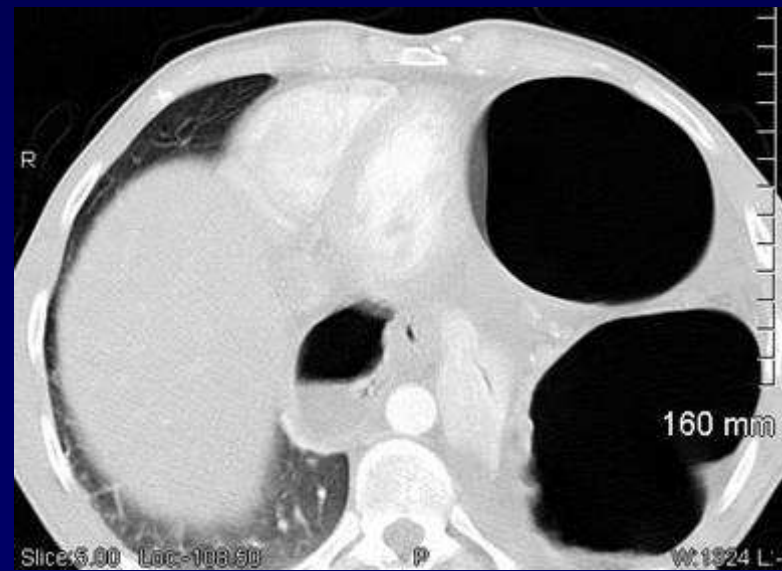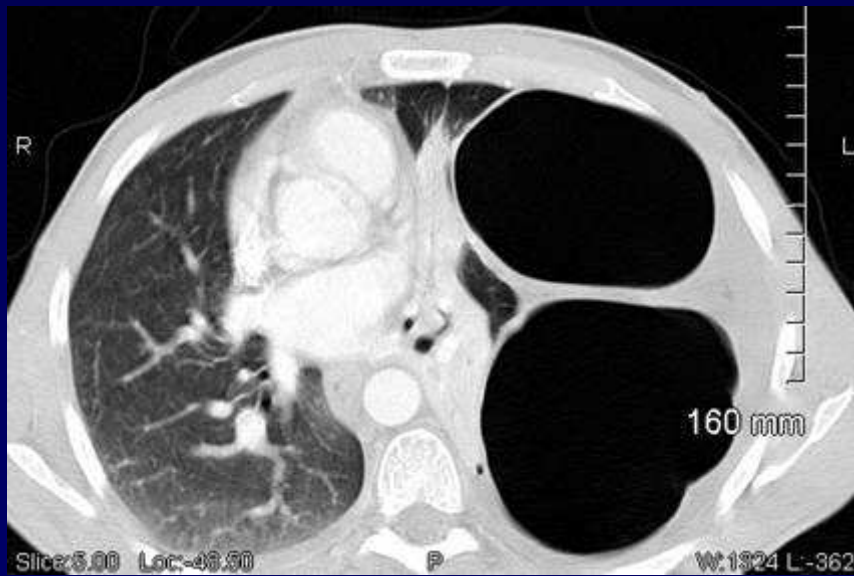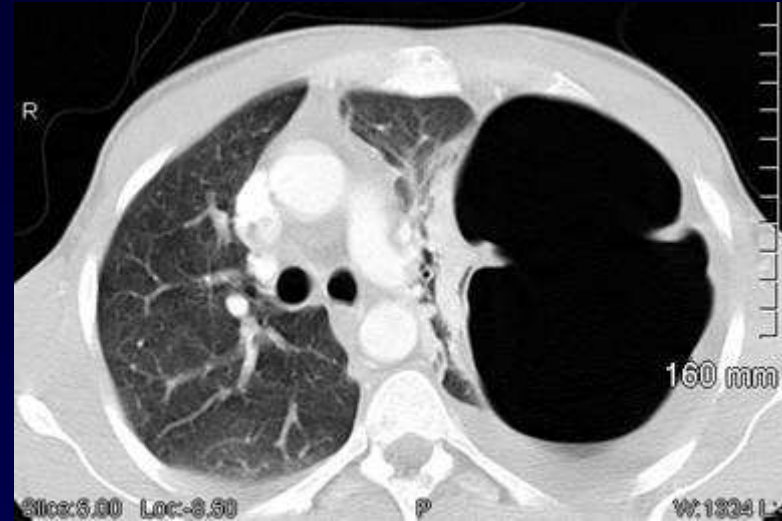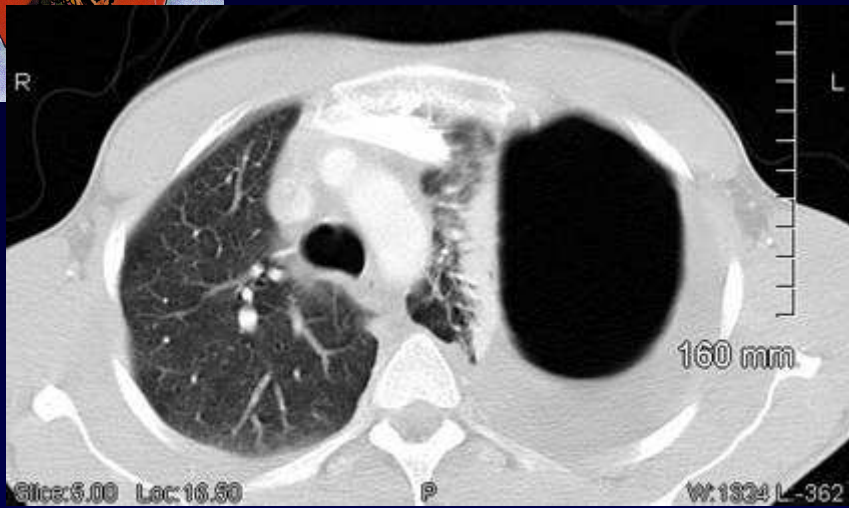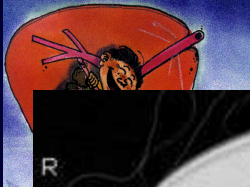Homme , 30 ans.

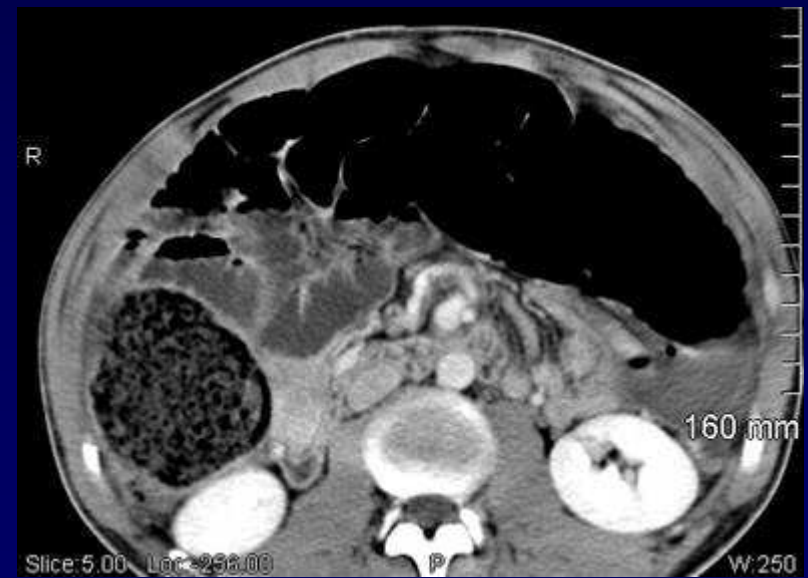
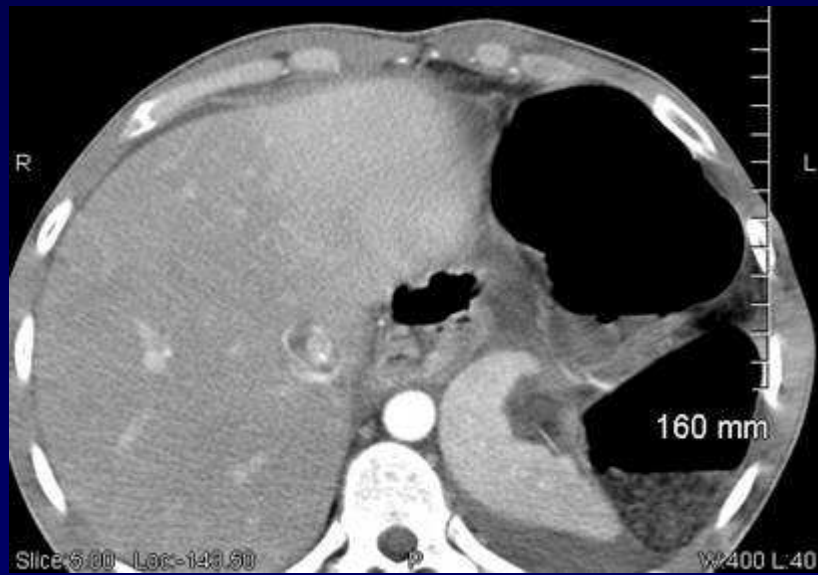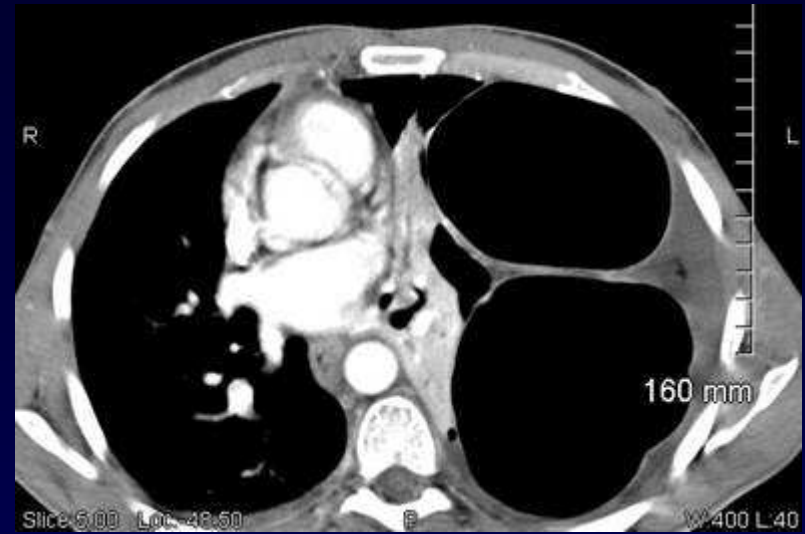
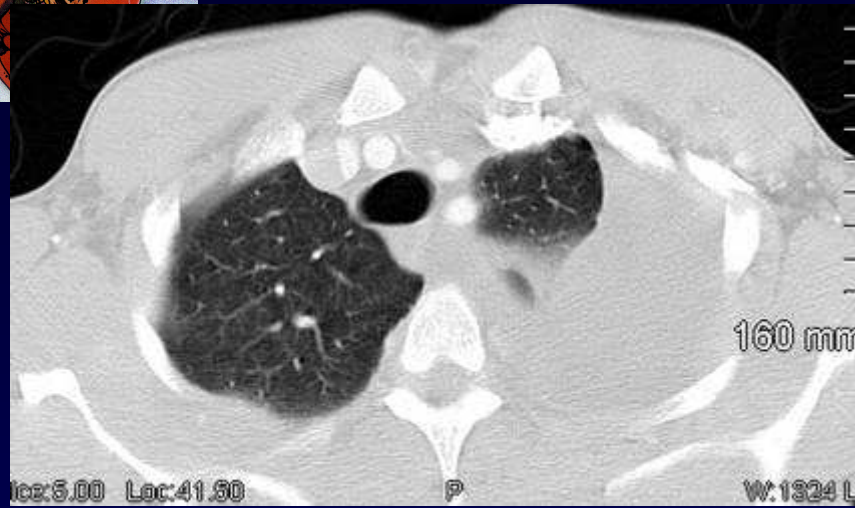

Dyspnée variable depuis un AVP il y a 1 an

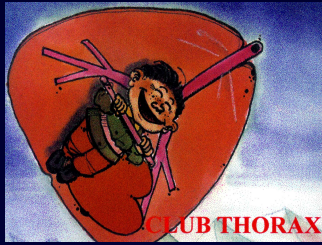
Admis aux urgences pour syndrome occlusif



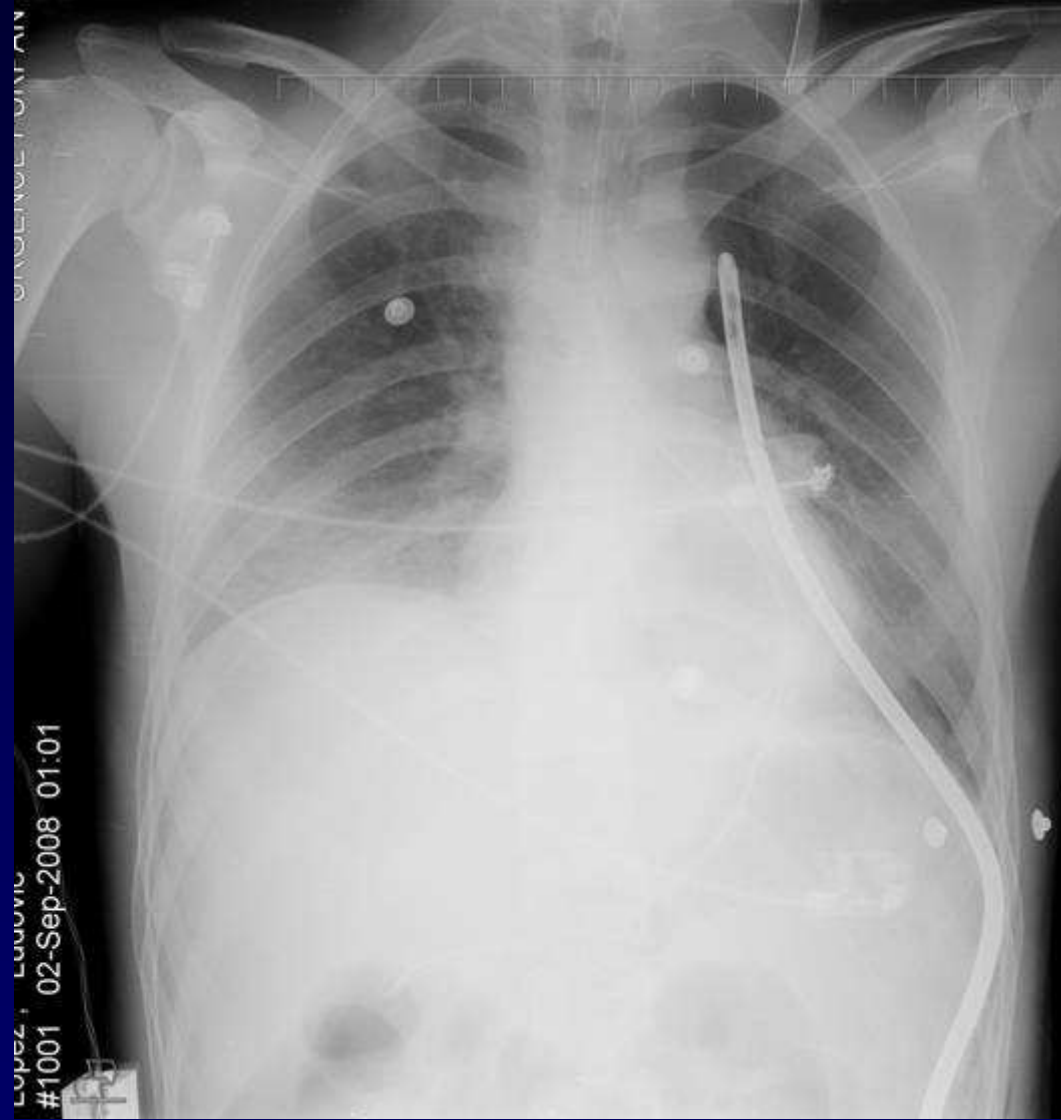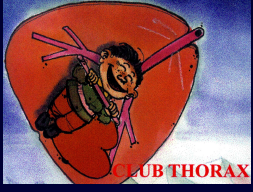


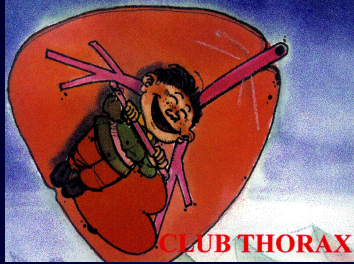






Diagnostic ?





Diagnostic

Rupture du diaphragme gauche
Hernie colique gauche et splénique
Hémi-colectomie gauche.
Rate conservée

Codage :Paroi – Diaphragme - Traumatique